

Animation Deformity in Postmastectomy Implant-Based Reconstruction

Lauren C. Nigro, MD
Nadia P. Blanchet, MD

Background: Despite increasing interest in prepectoral implant-based reconstruction to avoid animation deformity (AD), the prevalence of this deformity and patient attitudes toward it have not been extensively studied. The purpose of this study was to report on AD in the breast reconstruction population and identify those at highest risk.

Methods: A retrospective chart review was completed for patients at least 6 months postoperative from subpectoral, implant-based breast reconstruction using acellular dermal matrix in the lower pole. Patient age, BMI, and implant size were collected. A questionnaire was distributed to the patients. Returned questionnaires were compiled and data were analyzed.

Results: Eighty-four of 108 patients (77.8%) returned the questionnaire with 62 (75.6%) reporting AD; 75.6% of patients were aware of AD, 14.6% considered it moderate, and 11% considered it severe. No statistically significant differences in age, body mass index, implant size, or athleticism were found between those who noted AD versus those who did not. Forty-one of 79 patients (51.9%) would have been interested in an initial surgical procedure without AD; interest dropped significantly if the alternative surgery involved increased risk, cost, or additional stages of reconstruction.

Conclusion: The prevalence of AD in subpectoral implant-based breast reconstruction is significantly higher than in subpectoral augmentation. The majority of patients expressed interest in an alternative procedure to avoid AD unless it involved increased risk, cost, or additional surgeries. We found insignificant differences in age, athleticism, BMI, and implant size between patients who note AD and those who do not. Further study is necessary to better define patients at risk for AD to guide patient-centered breast reconstruction. (*Plast Reconstr Surg Glob Open* 2017;5:e1407; doi: 10.1097/GOX.0000000000001407; Published online 24 July 2017.)

INTRODUCTION

Animation deformity (AD), including its prevalence and effect on patients, has been studied in the context of subpectoral augmentation mammoplasty.¹ However, to our knowledge, only 1 other study has defined the prevalence and effect of AD in the subpectoral implant-based breast reconstruction patient population.² Given the recent rise in prepectoral, implant-based reconstruction, an assessment of patient experience with AD in the partial subpectoral implant-based reconstruction population is timely and relevant.

From the Division of Plastic and Reconstructive Surgery, Department of Surgery, Virginia Commonwealth University, Richmond, Va.

Received for publication May 10, 2017; accepted May 19, 2017.

Copyright © 2017 The Authors. Published by Wolters Kluwer Health, Inc. on behalf of The American Society of Plastic Surgeons. This is an open-access article distributed under the terms of the Creative Commons Attribution-Non Commercial-No Derivatives License 4.0 (CCBY-NC-ND), where it is permissible to download and share the work provided it is properly cited. The work cannot be changed in any way or used commercially without permission from the journal.

DOI: 10.1097/GOX.0000000000001407

METHODS

This study was approved by the Virginia Commonwealth University Institutional Review Board. Patients included in the study were reconstructed using a tissue expander and perforated, crescent-shaped acellular dermal matrix (ADM) in the lower pole for the first stage, followed by replacement with a silicone implant 2–3 months later, or direct-to-implant using ADM in the same position. In general, in larger breast reconstructions, more of the pectoralis muscle was detached and a larger proportion of ADM was used to recreate the inferior pole. The senior author performed all procedures (N.B.).

A questionnaire was mailed to all patients who had undergone subpectoral, implant-based breast reconstruction with ADM from January 1, 2012, to March 30, 2016 (see document, **Supplemental Digital Content 1**, which displays

Disclosure: The authors have no financial interest to declare in relation to the content of this article. The Article Processing Charge was paid for by the authors.

Supplemental digital content is available for this article. Clickable URL citations appear in the text.

the postmastectomy reconstruction questionnaire, <http://links.lww.com/PRSGO/A477>). This was distributed during breast cancer awareness month and was presented to patients as a study that could potentially help future mastectomy patients. Patients were asked if they notice AD, which was defined as a “twitching or movement of the upper portion of the breast with certain muscle movements of the arms or chest” and if so, how bothersome they found it on a scale of 1–10 (1 being not at all, 10 being disabling). They were then asked their level of athleticism with the same scale (1 being not athletic, 10 being extremely athletic). Lastly, they were asked their interest in an initial alternative procedure that would have eliminated AD and whether they would still have been interested if the procedure involved increased risk, cost, or additional fat grafting procedures. Patients were provided prestamped envelopes for returning the questionnaires. Data recorded included patient age, preoperative and most recent BMI, and implant size. All returned questionnaires were compiled, and data were analyzed using SAS 9.4 (SAS Institute Inc., Cary, N.C.). When patients had bilateral implants, the larger of the 2 implant sizes was used for analysis. Our scale for gauging degree of AD, from 1–10, was converted to the categories none, minimal, mild, moderate, and severe for comparison with Spear’s breast augmentation cohort (Fig. 1).¹ All tests were 2-tailed tested and used a significance level of 0.05. Due to the nonnormal distribution of the continuous variables, the nonparametric tests, Spearman correlation, and Wilcoxon 2-sample rank sum test, were used for the analyses. Categorical variables were compared using Fisher’s exact test.

RESULTS

One hundred eight patients were identified by chart review and mailed questionnaires. Eighty-four returned the questionnaire for a response rate of 77.8%; however, 1 patient was not included in data analysis as her implant had been explanted before the study, and every patient did not answer every question. All patients were at least 6 months postoperative extending up to 6 years postoperative. Patient characteristics are shown in Table 1.

Twenty of 82 patients (24.4%) were unaware of AD, 41 (50.0%) considered it minimal or mild, 12 (14.6%) considered it moderate, and 9 (11.0%) considered it severe (Fig. 1). The degree of AD is significantly higher than the degree of AD found by Spear et al.¹ in breast augmentation ($P = 0.0051$, Fisher’s exact test; Fig. 1).

Patient age, BMI, implant size, and level of perceived athleticism did not significantly differ between those who noted AD and those who did not (Table 2). In those who noted AD, there was a small, negative correlation between preoperative/recent BMI and the degree of AD ($-0.12953/-0.10188$) in which the lower the BMI the more noticeable the AD; similarly, there was a negative correlation between implant size and the degree of AD (-0.11812 ; Spearman correlation coefficients). These correlations were not statistically significant.

Forty-one of 79 patients (51.9%) would have been interested in an alternative surgical procedure to avoid AD at the time of the original mastectomy. If the procedure involved additional fat grafting, interest dropped to 50%; if it involved increased cost, interest dropped to 34.1%; if it involved increased risk, interest dropped to 8.9% (Fig. 2).

DISCUSSION

AD, also referred to as dynamic breast deformity or dynamic distortion, describes the perceived unnatural or exaggerated movement of the pectoralis muscle and/or subjacent implant with pectoralis contraction. This may not only be unsightly and embarrassing for the breast reconstruction patient but may also cause discomfort with certain activities; in more extreme cases, AD can be emotionally and physically debilitating.² Although Spear et al.¹ found that 53% of patients note AD after submuscular breast augmentation, we found this number to be notably higher in the breast reconstruction population (75.6%). This difference would be anticipated due to the absence of the breast parenchyma to camouflage the deformity, as well as the probability of more aggressive muscle separation inferomedially to accommodate generally larger breast reconstruction implants. Compared with the recent study by Becker and Fregosi², our patients were slightly

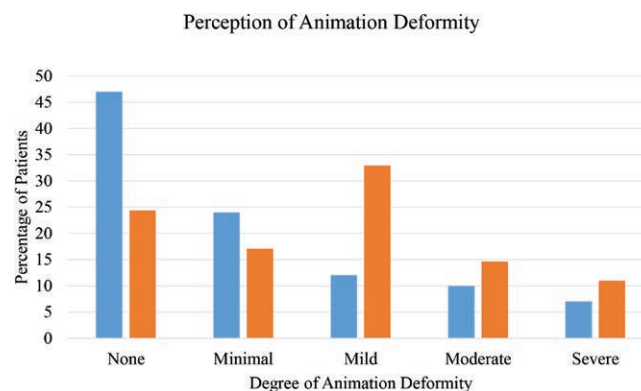


Fig. 1. Patient perception of AD in percentages, where minimal is 1–2.5, mild is 3–5, moderate is 5.5–7.5, severe is 8–10 on the questionnaire asking the degree of AD and how bothersome it is. The blue series represents Spear’s data. The orange series represents our data.

less aware of AD (75.6% versus 80%). Whereas Becker and Fregosi² found that 36% of patients experienced severe AD, 11% of ours experienced severe AD. Perhaps, this is due to Becker and Fregosi's² relatively small sample size, potential differences in severity scales, or that 28% of their patients were scheduled for revisions and perhaps self-selected.

We anticipated that more athletic patients, likely being more active and more muscular, would be more bothered by AD. Although there was a small difference, it was not statistically significant. We felt that BMI might correlate with AD anticipating that thinner patients with less fat grafting available would be more affected, or that larger patients with larger implants would have exaggerated AD as more muscle was detached to accommodate a larger implant. None of these hypotheses proved to be correct.

Table 1. Patient Characteristics

Characteristics	Value
Mean age in years	49.9
Age range in years	26.0–73.5
Mean preoperative BMI	24.7
Preoperative BMI range	18–38
Mean recent BMI	25.1
Recent BMI range	18–38
Mean implant size in mL*	520.3
Range implant size in mL	255–800
Mean perceived level of athleticism†	6

*When patients had bilateral implants, we used the larger of the 2 for data analysis.

†On a scale of 1–10, 1 being not athletic, 10 being extremely athletic.

Table 2. Comparison of Patients Who Noted AD after Subpectoral Breast Reconstruction with Those Who Did Not

Patient parameters	AD	No AD	P*
Mean age in years	50.7	47.4	0.2546
Mean preoperative BMI	24.5	25.3	0.5083
Mean recent BMI	24.7	26.2	0.2066
Mean implant size in mL†	521.9	514	0.891
Mean perceived level of athleticism‡	6.2	5.6	0.3345

*Calculated by Wilcoxon 2-sample test.

†When patients had bilateral implants, we used the larger of the 2 for data analysis.

‡On a scale of 1–10, 1 being not athletic, 10 being extremely athletic.

Methods to reduce AD, in both augmentation and reconstruction, have been explored. These include pectoralis muscle splitting or sectioning techniques and chemical or mechanical muscle denervation.^{3–7} With the advantages of ADM and fat grafting, prepectoral breast reconstruction is being performed with increased frequency.^{8–15} Subcutaneous implant-based breast reconstruction was popular in the early 1980s but was largely abandoned and replaced with submuscular implant-based breast reconstruction because of the concerns for implant visibility, palpability, malposition, encapsulation, rippling, extrusion, infection, and wound healing issues.¹⁶ With the relatively recent advent of ADM for anterior coverage of prostheses, and reliable fat grafting, prepectoral breast reconstruction has been revisited with the advantages of elimination of AD as well as shorter operative times and easier postoperative recovery.¹⁷ Acceptable encapsulation, infection, and flap necrosis rates have been reported.¹⁴ Understanding of the disadvantages of this new generation of subcutaneous implant-based breast reconstruction is evolving. Oncologic surgeons may not be comfortable with thicker, more robust mastectomy flaps, which are ideal for prepectoral reconstruction. Perfusion systems that guide intraoperative decisions have been advocated but may not always be available.¹⁸ Implant visibility and rippling remains an issue that can be ameliorated but perhaps not always eliminated by fat grafting, despite more cohesive implants. Stability of the footprint of the reconstruction may be more problematic as it depends entirely on stabilization of the ADM pocket on the chest wall and may prove to be an issue with larger implants. The issue of increased cost should not be ignored; covering the implant with ADM can incur tens of thousands of dollars of increased cost, which although currently covered by most insurance policies, does ultimately contribute to overall health-care costs of mastectomy patients. Minor wounds need to be excised early as the skin buttressed only by ADM may not heal as readily as more robust flaps.¹⁵ It remains to be seen whether these flaps will remain more prone to skin injury, wound healing problems, or radiation injury. As with autologous reconstruction, the footprint of the original breast is now covered by the reconstruction, so chest wall recurrences

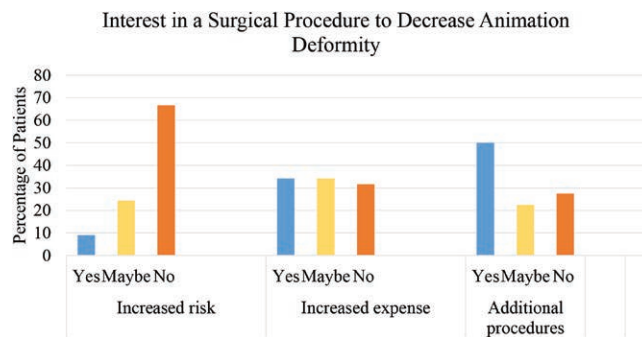


Fig. 2. Patient interest in an initial surgical procedure, which would have avoided AD, broken down by patient interest if the procedure involved increased risk, increased expense, or additional procedures (e.g., fat grafting).

will be harder to detect. Finally, as this is a relatively new procedure, we do not have long-term follow-up studies.

Although the patient population was drawn from a single surgeon's practice, we believe this eliminated variation in surgical technique as a variable when assessing patients' experience with AD. We attribute our high response rate (77.8 %) to heightened patient motivation to help other patients who have undergone mastectomy and reconstruction during October, which is breast cancer awareness month. We recommend that future questionnaire-based studies use similar timing. Despite this high response rate, it is possible that our study lacked the power to show statistically significant differences between those who noted AD and those who did not. Several other limitations should be noted: we did not take into account whether patients underwent radiation and how this may have affected AD. We did not address timing as a variable; perhaps AD improves or worsens with time. We lack objective data from nonself observers, although we postulate that since this is a quality of life issue, the patient's self-perception is actually more important than the opinion of outside observers. We failed to ask our patients about pain, as this is another reported disadvantage of subpectoral breast reconstruction. Cost as a variable was not qualified in terms of personal cost or increased health-care cost in general so this metric in our survey is unfortunately of limited value. Lastly, as with any questionnaire-based study, there is inherent sampling bias. Despite these limitations, this study presents the prevalence and severity of AD in a group of 84 patients and the extent to which patients may be willing to make compromises to avoid it.

CONCLUSIONS

As anticipated, the prevalence of AD in subpectoral implant-based breast reconstruction is higher than in subpectoral breast augmentation. We found small, albeit insignificant, differences in age, BMI, implant size, and athleticism between patients who note AD and those who do not. Although approximately half of patients would have been potentially interested in an initial procedure that reduces AD, they were much less interested if this involved increased risk, cost, or additional surgeries. Therefore, although AD is quite debilitating for some patients, we did not find an overwhelming mandate among our patients for a complete reimagination of implant-based breast reconstruction. We are not arguing against prepectoral breast reconstruction, which is an exciting new innovation, but would like to place AD in a patient-centered context. It may be an issue that is more disturbing to us as surgeons than it is to our patients. Unfortunately, we were unable to determine which patients are at highest risk for AD, and future studies are needed in this area. Patients should be aware of the advantages and disadvantages of each technique as our knowledge evolves so that they may make informed choices.

Nadia P. Blanchet, MD

Stony Point Professional Park
9210 Forest Hill Ave Suite B-1
Richmond, Virginia 23235 d
E-mail: nadia@nadiablanchet.com

ACKNOWLEDGMENTS

We would like to acknowledge Dawn Sykes, Luke Wolfe, MS, and Maryann Martinovic, MD, for their assistance with data collection, statistical analysis, and editing.

REFERENCES

1. Spear SL, Schwartz J, Dayan JH, et al. Outcome assessment of breast distortion following submuscular breast augmentation. *Aesthetic Plast Surg*. 2009;33:44–48.
2. Becker H, Fregosi N. The impact of animation deformity on quality of life in postmastectomy reconstruction patients. *Aesthet Surg J*. 2017;37:531–536.
3. Pelle-Ceravolo M, Del Vescovo A, Bertozzi E, et al. A technique to decrease breast shape deformity during muscle contraction in submuscular augmentation: mammoplasty. *Aesthetic Plast Surg*. 2004;28:288–294.
4. Baxter RA. Update on the split-muscle technique for breast augmentation: prevention and correction of animation distortion and double-bubble deformity. *Aesthetic Plast Surg*. 2011;35:426–429.
5. Saleh DB, Callear J, Riaz M. An anatomic appraisal of biplanar muscle-splitting breast augmentation. *Aesthet Surg J*. 2016;36:1019–1025.
6. Figus A, Mazzocchi M, Dessy LA, et al. Treatment of muscular contraction deformities with botulinum toxin type A after latissimus dorsi flap and sub-pectoral implant breast reconstruction. *J Plast Reconstr Aesthet Surg*. 2009;62:869–875.
7. Richards A, Ritz M, Donahoe S, et al. Botox for contraction of pectoral muscles. *Plast Reconstr Surg*. 2001;108:270–271.
8. Becker H, Lind JG, 2nd, Hopkins EG. Immediate implant-based prepectoral breast reconstruction using a vertical incision. *Plast Reconstr Surg Glob Open*. 2015;3:e412.
9. Bernini M, Calabrese C, Cecconi L, et al. Subcutaneous direct-to-implant breast reconstruction: surgical, functional, and aesthetic results after long-term follow-up. *Plast Reconstr Surg Glob Open*. 2015;3:e574.
10. Caputo GG, Marchetti A, Dalla Pozza E, et al. Skin-reduction breast reconstructions with prepectoral implant. *Plast Reconstr Surg*. 2016;137:1702–1705.
11. Hammond DC, Schmitt WP, O'Connor EA. Treatment of breast animation deformity in implant-based reconstruction with pocket change to the subcutaneous position. *Plast Reconstr Surg*. 2015;135:1540–1544.
12. Kobraei EM, Cauley R, Gadd M, et al. Avoiding breast animation deformity with pectoralis-sparing subcutaneous direct-to-implant breast reconstruction. *Plast Reconstr Surg Glob Open*. 2016;4:e708.
13. Reitsamer R, Peintinger F. Prepectoral implant placement and complete coverage with porcine acellular dermal matrix: a new technique for direct-to-implant breast reconstruction after nipple-sparing mastectomy. *J Plast Reconstr Aesthet Surg*. 2015;68:162–167.
14. Salibian AA, Frey JD, Choi M, et al. Subcutaneous implant-based breast reconstruction with acellular dermal matrix/mesh: a systematic review. *Plast Reconstr Surg Glob Open*. 2016;4:e1139.
15. Sigalove S, Maxwell GP, Sigalove NM, et al. Prepectoral implant-based breast reconstruction: rationale, indications, and preliminary results. *Plast Reconstr Surg*. 2017;139:287–294.
16. Gruber RP, Kahn RA, Lash H, et al. Breast reconstruction following mastectomy: a comparison of submuscular and subcutaneous techniques. *Plast Reconstr Surg*. 1981;67:312–317.
17. Downs RK, Hedges K. An alternative technique for immediate direct-to-implant breast reconstruction—a case series. *PRSGlob Open* 2016;4:e821. doi:10.1097/GOX0000000000000839.
18. Mattison GL, Lewis PG, Gupta SC, et al. SPY imaging use in postmastectomy breast reconstruction patients: preventative or overly conservative? *Plast Reconstr Surg*. 2016;138:15e–21e.